

Chronic Scaphoid Nonunion of 28-Year Duration Treated with Nonvascularized Iliac Crest Bone Graft

John T. Capo, MD¹ Ben Shamian, MD¹ Steve Rivero, BS¹

¹Division of Hand and Microvascular Surgery, Department of Orthopaedics, UMDNJ-New Jersey Medical School, Newark, New Jersey

Address for correspondence John T. Capo, MD, NYU-Hospital for Joint Diseases, 301 East 17th St., New York, NY 10003 (e-mail: john.capo@nyumc.org).

J Wrist Surg 2013;2:79–82.

Abstract

Keywords

- ▶ scaphoid nonunion
- ▶ chronic
- ▶ bone graft
- ▶ iliac crest

Scaphoid nonunions present a challenging clinical problem, particularly if the diagnosis of nonunion is missed or delayed. The optimal management technique can vary from free vascularized bone grafts to scaphoid excision and limited wrist fusion. The classic method of open reduction, nonvascularized corticocancellous bone grafting and internal fixation is still an effective technique. In this report, we describe a case of a 28-year-old chronic scaphoid nonunion treated with nonvascular iliac crest bone graft and internal fixation.

Nonunion of the scaphoid is most often defined as failure of solid bony union of the scaphoid fracture after 4 to 6 months. Patients with nonunions occasionally delay seeking treatment for many months or years after the initial injury because the symptoms can be minimal.¹ The most common treatment approach for nonunions is operative management involving bone grafting and internal fixation. The progression of untreated scaphoid nonunions to secondary radiocarpal osteoarthritis and eventually carpal collapse is well described.^{2–4} In this report, we present a case of a 28-year-old chronic scaphoid nonunion treated with a nonvascular bone graft achieving excellent clinical and radiographic outcomes.

Case Report

The patient is a 47-year-old right-hand-dominant male who injured his right wrist 28 years prior to his presentation after falling off a truck in 1982. The patient gave a history that he suffered a scaphoid fracture at that time. He was treated initially with immobilization in a cast for 6 months. Over the next 1 to 3 years he had mild pain but refused multiple offerings of operative management. His pain subsided after that and he had only mild limitations and occasional pain over the next 23 years. Medical records from 1996 obtained from the Veterans Administration hospital verified his history, and an X-ray report at that visit confirmed a scaphoid nonunion.

Before the patient presented to our office, he had a 2-year period of steadily increasing pain in the wrist. He was seen and evaluated by a plastic surgeon for right wrist pain and numbness for the duration of 11 months. Physical exam (positive Tinel, Phalen, and compression test) and electromyogram (EMG) were consistent with carpal tunnel syndrome, for which he underwent operative treatment. The patient was referred to us for further evaluation of his persistent wrist pain. He denied any history of recent trauma.

He was becoming more limited in his daily activities. On physical exam of his wrist, he displayed discrete tenderness over the scaphoid and radioscaphoid joint dorsally. Wrist range of motion (ROM) showed wrist extension to 45 degrees and flexion to 40 degrees, pronation to 80 degrees, and supination of 80 degrees. His grip strength was limited to approximately 50% of the other side. He had a normal motor and sensory exam. Watson test was negative for scapholunate instability, but he had pain with forced radial deviation. Radiographs at that time showed a chronic nonunion of the waist of the scaphoid with mild cystic changes of the proximal scaphoid fragment. There was a mild dorsal intercalated segmental instability pattern with a scapholunate angle of 79 degrees. His carpus was representative of a stage I scapholunate advanced collapse pattern with narrowing of joint between the distal radius and distal scaphoid pole (▶ **Figs. 1 and 2**). As compared with his contralateral films,

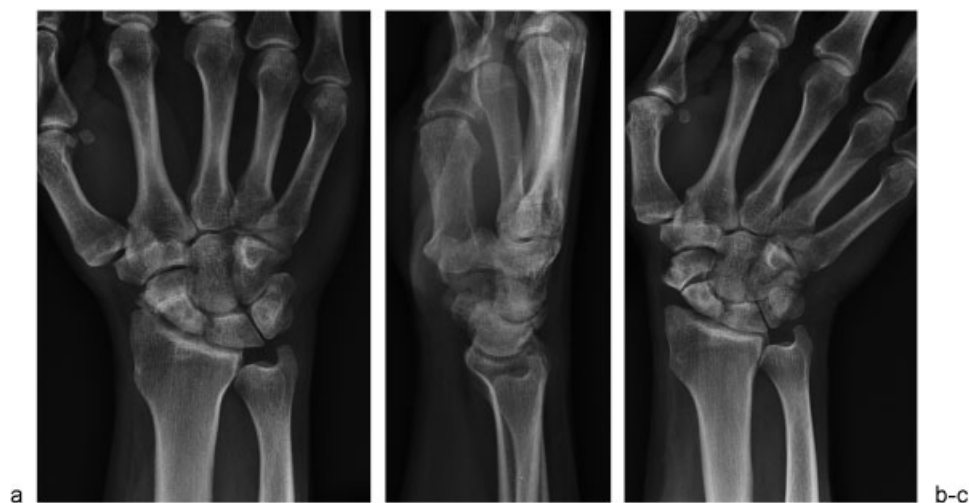


Fig. 1 (a) Anteroposterior (b) and lateral preoperative radiographs showing scaphoid nonunion with carpal collapse and mild cystic changes. (c) Ulnar deviation view demonstrating large defect in the scaphoid.

he had 4.5 mm of scaphoid shortening, and 30 degrees of scaphoid flexion.

Due to his unrelenting pain, he wished to proceed with surgical treatment. He was taken to the operating room for open reduction and internal fixation of his scaphoid nonunion with a nonvascularized iliac crest bone graft. A volar radial incision was made centered over the scaphoid and the flexor carpi radialis (FCR) sheath. The FCR tendon was unroofed and retracted ulnarly, and the floor of the sheath was opened. The scaphoid was found to have a clear nonunion with instability of the two fragments. There was minimal evidence of radioscaphoid arthritis. Kirschner (K)-wire joysticks were placed in each fragment of the scaphoid to expose

the nonunion site. The nonunion site was drilled with a 0.045 K-wire and irrigated. This induced bleeding from the cancellous bone of the proximal and distal fragments. Next, the iliac crest bone graft was taken from a 4-cm incision over the anterior iliac crest. A $7 \times 5 \times 12$ -mm corticocancellous tricortical graft was obtained. Additional cancellous graft was taken from between the inner and outer tables of the ilium.

The cancellous graft was first placed in the interstices of the proximal and distal scaphoid poles. The corticocancellous graft was then fashioned to fit the resulting structural defect and was impacted into place. Intra-operative imaging showed good restoration of the alignment of the scaphoid and a normal scapholunate angle. A 0.045 K-wire was used to pin

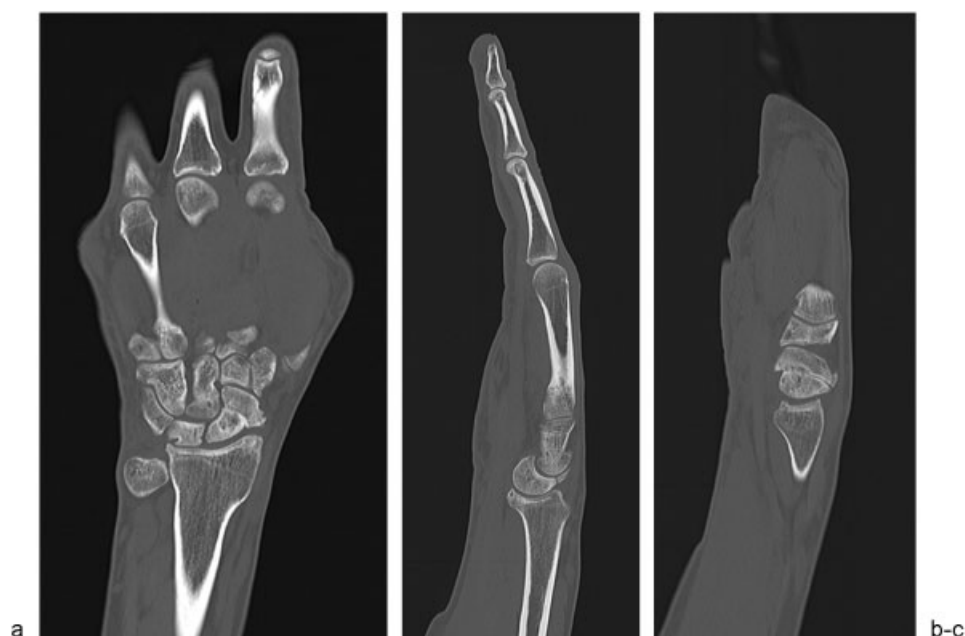

Fig. 2 Computed tomography scan images of the collapsed scaphoid. (a) Frontal view shows shortening of the scaphoid and large radial osteophyte. (b-c) Sagittal view demonstrates DISI deformity and shortening of scaphoid with humpback deformity.

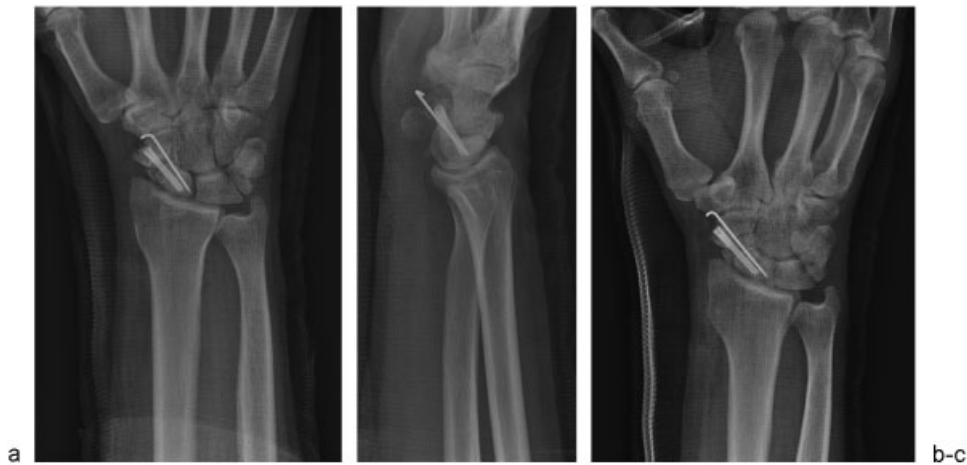

Fig. 3 (a) Anteroposterior (b) lateral (c) and oblique radiographs demonstrating restoration of the scaphoid normal anatomy with placement of a structural graft. The construct is stabilized with a cannulated headless screw and a de-rotational Kirschner wire.

the graft into place, followed by a headless screw (Acutrak, Acumed, Beaverton, OR) in the central portion of the scaphoid. The de-rotational K-wire was cut, then bent and left in place under the skin. (►**Fig. 3**). Additional cancellous graft was packed in around the nonunion. The radioscapocapitate ligament was repaired and the incisions on the wrist and iliac crest were closed in standard fashion. All wounds were dressed sterilely, and the patient was placed in a well-fitting thumb spica splint

Postoperatively, he was placed in a short arm cast and instructed to avoid heavy lifting. He was treated with an external bone stimulator beginning at 1 week postoperatively. The patient remained in the cast until bony healing was noted at 4 months postoperatively. At that time, he returned to the operating room for removal of the deep buried pin. At 6 months postoperative, radiographs showed complete healing with callus remodeling of the scaphoid nonunion (►**Fig. 4**). On physical exam at 6 months postoperatively, the patient had mild tenderness over the right wrist in the

anatomic snuff-box. Sensation was intact in all nerve distributions. Range of motion of the right wrist demonstrated extension of 40 degrees, flexion of 45 degrees, pronation of 80 degrees, and supination of 80 degrees. His DASH (Disabilities of the Arm, Shoulder, and Hand) score at this point was 36. Grip strength in his injured hand was 64% of the contralateral side.

Discussion

Cases of treatment of chronic nonunion have been reported in the literature with poor outcomes. Shah et al⁵ reviewed 50 patients treated with wedge grafting and Herbert screw fixation. Fourteen of these patients had chronic nonunions of 5 to 25 years duration, and the remaining 36 patients underwent surgery within 5 years of the initial injury. In the patients with chronic nonunions, they achieved a union rate of 57%, compared with a union rate of 88% in patients treated within 5 years. Nakamura et al¹ showed that patients with at least 5-year duration of injury were much less likely to have an excellent or good surgical outcome. They operated on 12 patients with longstanding nonunions of 5 to 30 years. Of these patients, only 1 of the 12 had an excellent or good outcome. The patient of 30-year duration was not described in detail, and the results of this case were not clearly defined. This is the only report that mentions a scaphoid nonunion treated with surgery of longer duration than our case.

The literature is limited in reporting on the successful surgical treatment of chronic scaphoid nonunions of over 25 years' duration. Our case is the longest reported duration of delayed treatment of scaphoid nonunion treated with surgical fixation and bone grafting that resulted in bony healing and a good clinical outcome. A surprising feature of this case is the relative paucity of degenerative changes at the radioscapoid joint, which suggests that the natural history of a chronic scaphoid nonunion does not always culminate in progressive radiocarpal and midcarpal OA.

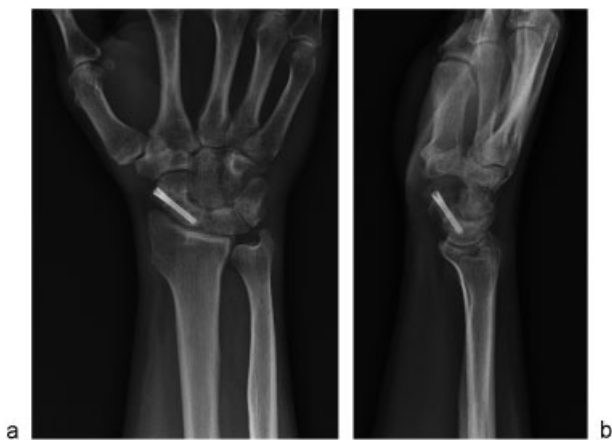


Fig. 4 (a) Anteroposterior (b) and lateral views demonstrating the final radiographic outcome at 6 months postoperatively. The scaphoid is completely healed with remodeling of the nonunion site.

References

- 1 Nakamura R, Horii E, Watanabe K, Tsunoda K, Miura T. Scaphoid non-union: factors affecting the functional outcome of open reduction and wedge grafting with Herbert screw fixation. *J Hand Surg [Br]* 1993;18(2):219-224
- 2 Mack GR, Bosse MJ, Gelberman RH, Yu E. The natural history of scaphoid non-union. *J Bone Joint Surg Am* 1984;66(4):504-509
- 3 Simonian PT, Trumble TE. Scaphoid nonunion. *J Am Acad Orthop Surg* 1994;2(4):185-191
- 4 Ruby LK, Stinson J, Belsky MR. The natural history of scaphoid non-union. A review of fifty-five cases. *J Bone Joint Surg Am* 1985;67(3):428-432
- 5 Shah J, Jones WA. Factors affecting the outcome in 50 cases of scaphoid nonunion treated with Herbert screw fixation. *J Hand Surg [Br]* 1998;23(5):680-685